

## PATIENT

Maggie Hernandez

## SPECIES

Canine

## BREED

Shih Tzu

## SEX

FS

## AGE

16

## WEIGHT

11.6

## INTERPRETED BY

R. McKenzie Daniel,  
DVM, DABVP  
(Canine and Feline)

## IMAGING PERFORMED BY

Jenn

## HOSPITAL NAME

Rockaway Animal  
Hospital

## REFERRING VET

Dr Maniar

## INVOICE 24207

**DATE**  
03/16/2026

## PRESENTING CLINICAL SIGNS

Diarrhea with blood anorexia lethargy

## ULTRASONOGRAPHIC EXAMINATION OF THE ABDOMEN

### Urinary System

The urinary bladder, trigone, cystourethral junction, and visible pelvic urethra exhibited normal thickness and tone. Anechoic urine was present in the lumen with no evidence of urine/lumen sediment, mineral, or calculi. The ureteral papillae were normal. The ureters were not visible which is normal. No evidence of inflammatory or neoplastic changes was noted.

Normal size and margination were present in the kidneys. A normal 1:3 cortex / medulla ratio was maintained. The medulla and cortices were uniform in texture with some increased echogenicity and mild loss of corticomedullary symmetry and definition expected for the age of the patient. No evidence of pelvic dilation was present. Bilateral areas of focal medullary mineral were present. The left kidney measured 3.6 cm in length. The right kidney measured 3.6 cm in length.

The area of the aortic trifurcation was free of pathology.

### Adrenal Glands

The left adrenal gland was uniform in size and contour with a uniformly hypoechoic parenchyma. The left adrenal gland measured 0.53 cm width at the caudal pole. The right adrenal gland was uniform in size and contour with a uniformly hypoechoic parenchyma. The right adrenal gland measured 0.64 cm width at the caudal pole.

### Spleen

The spleen exhibited a finely textured and homogenous parenchyma which was hyperechoic to the liver and renal cortical parenchyma. The capsule was smooth and regular without apparent expansion. The splenic vasculature at the hilus was normal in volume with no evidence of congestion or thrombosis. Acute to chronic inflammatory, neoplastic, or benign parenchyma changes were not noted.

### Liver/Gallbladder

The liver was subjectively normal in size, structure, and contour. The liver parenchyma was mildly nonuniform and hypoechoic to the spleen with a moderate coarse echotexture and subjective mild to benign parenchymal remodeling. The hepatic and portal vasculature were normal in appearance without signs of congestion. The gallbladder was non-distended in size with thin walls and mild non-organized debris. The cystic and common bile ducts were normal.

### Gastrointestinal

The stomach presented intact wall layering with a normal wall layer ratio. The lumen of the stomach was empty with no signs of ileus, obstruction or foreign material.

The small intestine presented intact wall layering with 1:3 muscularis/mucosa ratio. The lumen of the small intestine was empty with no signs of mechanical/metabolic ileus, obstruction or foreign material.



## PATIENT

Maggie Hernandez

The descending colon walls presented intact yet mild thickened wall layering. Soft fecal matter and lumen gas was present in the non-distended colon.

### *Pancreas*

## SPECIES

Canine

The parenchyma of the left limb, body and right limb of the pancreas presented isoechoic to the adjacent omental fat. A normal curvilinear capsule contour of the pancreas was present. The visible pancreatic duct was normal. No signs of active inflammation or neoplastic disease was evident.

### *Free Abdomen*

## BREED

Shih Tzu

No omental masses, overt lymphadenopathy or peritoneal effusion was present.

## ULTRASONOGRAPHIC FINDINGS

## SEX

FS

### Primary

- Colitis pattern with sonographically unremarkable empty gastrointestinal tract
- Normal area of pancreas
- Age-related kidneys with focal medullary mineral
- Mild gallbladder debris (non-mucocele)

## AGE

16

## INTERPRETATION OF THE FINDINGS & FURTHER RECOMMENDATIONS

## WEIGHT

11.6

Supportive care for colitis with possible structurally insignificant gastroenteritis is recommended. No evidence of gastroenterocolic foreign material or overt abdominal neoplastic criteria. Sonographic reassessment indicated if progressive gastrointestinal signs.

## INTERPRETED BY

R. McKenzie Daniel,  
DVM, DABVP  
(Canine and Feline)

## IMAGING PERFORMED BY

Jenn

## HOSPITAL NAME

Rockaway Animal  
Hospital

## REFERRING VET

Dr Maniar

## INVOICE

24207

## DATE

03/16/2026



**PATIENT**

Maggie Hernandez

**SPECIES**

Canine

**BREED**

Shih Tzu

**SEX**

FS

**AGE**

16

**WEIGHT**

11.6

**INTERPRETED BY**

R. McKenzie Daniel,  
DVM, DABVP  
(Canine and Feline)

**IMAGING PERFORMED BY**

Jenn

**HOSPITAL NAME**

Rockaway Animal  
Hospital

**REFERRING VET**

Dr Maniar

**INVOICE**

24207

**DATE**

03/16/2026





## PATIENT

Maggie Hernandez

## SPECIES

Canine

## BREED

Shih Tzu

## SEX

FS

## AGE

16

## WEIGHT

11.6

## INTERPRETED BY

R. McKenzie Daniel,  
DVM, DABVP  
(Canine and Feline)

## IMAGING PERFORMED BY

Jenn

## HOSPITAL NAME

Rockaway Animal  
Hospital

## REFERRING VET

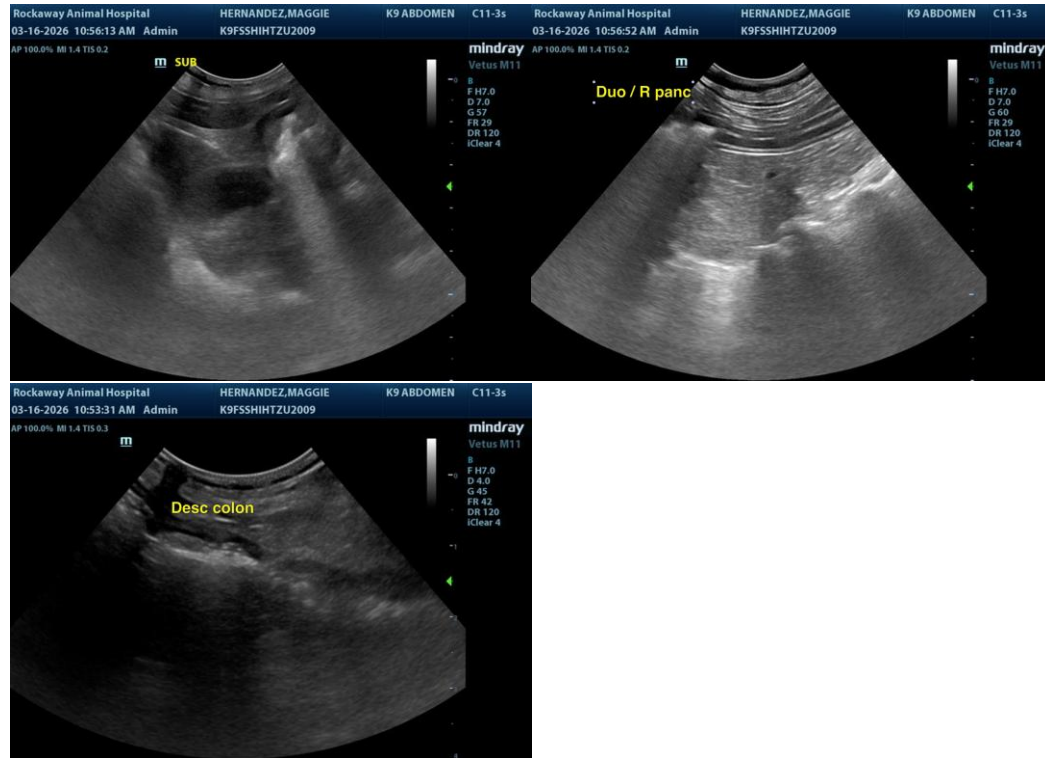
Dr Maniar

## INVOICE

24207

## DATE

03/16/2026



The information and recommendations provided are based on the images presented by the referring veterinarian/sonographer. No evaluation can be communicated regarding pathology that was not visible in the image/video clips provided.

Thank you for this referral. If the clinical or image interpretation does not parallel your findings or if I can be of any further assistance, please contact me.

R. McKenzie Daniel, DVM, DABVP (Canine/Feline Practice)  
[info@sonopath.com](mailto:info@sonopath.com)